



Comparative study in the management of allergic rhinitis in children using LED phototherapy and laser acupuncture

Yousry Moustafa^a, Ahmed Nazmi Kassab^{a,*}, Jehan el Sharnoubi^b, Hala Yehia^b

^a Otorhinolaryngology Unit, Department of Medical Laser Applications, National Institute of Laser Enhanced Sciences, Cairo University, Egypt

^b Pediatric Unit, Department of Medical Laser Applications, National Institute of Laser Enhanced Sciences, Cairo University, Egypt

ARTICLE INFO

Article history:

Received 27 September 2012

Received in revised form 5 January 2013

Accepted 9 January 2013

Available online 8 February 2013

Keywords:

Allergic rhinitis in children

LED

Laser acupuncture

ABSTRACT

Objective: The objective of this study was to compare the outcomes of LED phototherapy and laser acupuncture treatment on allergic rhinitis in children.

Methods: 40 patients with perennial allergic rhinitis were divided randomly into two groups. Patient's ages ranged from 7 to 18 years. One group was subjected to LED phototherapy and the other group was managed by laser acupuncture. The patients were followed-up for 1 year.

Results: There was a significant improvement in the severity score symptoms in both groups through and by the end of the follow up period.

Conclusion: This led to the conclusion that both techniques are equally safe, reliable, non invasive and successful.

© 2013 Elsevier Ireland Ltd. All rights reserved.

1. Introduction

Allergic rhinitis is one of the most common diseases in children. However, children frequently lack the ability to verbalize their symptoms with the result that the condition may go undiagnosed and untreated. Unfortunately, untreated allergic rhinitis not only detrimentally affect children physical and psychosocial well-being, quality of life, and capacity to function and learn, but it is also associated with and may contribute to potentially serious sequelae, including asthma, sinusitis, and otitis media [1].

The management scheme for the treatment of allergic rhinitis in the child is similar to that in the adult. Specifically, treatment options include environmental control for allergen avoidance, pharmacotherapy, acupuncture, soft laser phototherapy and immune-therapy. In all cases, the primary goal of treatment is to control the symptoms without altering the child's ability to function; a second but equally important goal is to prevent the development of the sequelae of allergic rhinitis [2].

The two major classes of pharmacological agents used to treat symptoms of allergic rhinitis are oral H¹ antihistamines and intranasal corticosteroids. These agents may be used as mono therapy or in combination, depending on the predominant symptoms and the patient's response to therapy. Alternative agents, such as Cromolyn sodium, may be appropriate in some patients [3].

The first generation of antihistamines relieve the symptoms of allergic rhinitis, but they cross the blood–brain barrier and are thus associated with marked drowsiness and impaired performance in school or work in adults [4]. Other side effects of the first generation antihistamines include blurred vision, urinary retention in young children, dry mouth, tachycardia, and constipation [5]. On the other hand, second generation antihistamines which are more lipophobic and therefore unable to cross the blood–brain barrier, are considerably less sedating [6–8].

Corticosteroids have been shown to be the most effective form of pharmacological treatment for pediatric allergic rhinitis. Data support the use of intranasal corticosteroids as first line therapy over oral antihistamines [9–12]. However reports of decreased bone growth in children receiving short-term intranasal Budesonide and long term Beclomethasone Di-Propionate have heightened concerns that some of these drugs may have systemic effects [13].

Subcutaneous immunotherapy (SCIT) is widely used for moderate–severe perennial and seasonal allergic rhinitis in adults. The role of SCIT in the treatment of allergic rhinitis and asthma in children remains somewhat controversial. Even more actively debated is the use and efficacy of sublingual immunotherapy (SLIT) in the pediatric population. SLIT is of great appeal to the pediatrician because of its ease of delivery and the potential to avoid frequent injections and serious side effects including the risk of fatal anaphylaxis, which are associated with the subcutaneous route [14,15].

Intranasal phototherapy with a combination of ultraviolet light (UV-B, UV-A) and visible light was effectively used in treating

* Corresponding author. Tel.: +20 1001469263.

E-mail address: Kassabahmed28@yahoo.com (A.N. Kassab).

allergic rhinitis as it reduced the number of inflammatory cells and level of mediators [16–19]. Light emitting diode (LED) was also shown to be of therapeutic potential. The output from LED can range from blue to violet (400 nm) to red (about 700 nm) some LEDs emit infrared (IR) energy (830 nm or longer) [20–22].

In addition to the previously mentioned methods, complementary and alternative medicines are now frequently used to treat allergic rhinitis worldwide. Over the past decade, acupuncture has been reported to be beneficial in a number of clinical studies on allergic rhinitis, which reported a significant improvement in daily symptoms and an increase of symptoms-free days [23,24].

Acupuncture involves the stimulation of specific points located along lines of meridians corresponding to the flow of energy through the body. Traditionally, these acupoints were stimulated using fine needles. Modern acupuncture has evolved to include the application of pressure, the use of electric current and use of low-intensity laser to stimulate the outpoints [25,26].

In this work, we conducted a comparative study of the efficacy of light emitting diode and laser acupuncture in the management of allergic rhinitis in children; as both are typically non-invasive and aseptic procedures.

2. Patients and methods

The candidates in this study were previously diagnosed to have perennial allergic rhinitis and referred from allergy pediatric clinical units based on definite rhinological symptoms, skin prick tests, positive specific IgE by RAST test against the commonest inhaled allergens (house dust mites, molds and feathers) and estimated high levels of total IgE.

Patients with severe nasal septum deviation, adenoids nasal polyposis, as well as those suffering from sinusitis as revealed by endoscopic and radiological examination were excluded from the study. Patients convalescing from an upper respiratory tract infection or had been using nasal or oral corticosteroids within 2 weeks before the start of the study were also excluded. The duration of nasal symptoms ranged from 6 months to 5 years, and the severity of symptoms were determined according to standardized severity scale and ranged from mild to moderate and severe symptoms [27].

The study group consisted of 40 patients with perennial allergic rhinitis divided randomly into two groups. Patient's ages ranged from 7 to 18 years.

The treatment sessions either by LED phototherapy or laser acupuncture was conducted in the National Institute of Laser Enhanced Sciences – Cairo University. The diagnosis of allergic rhinitis was based on definite symptoms of nasal itching, rhinorrhea, sneezing and nasal obstruction. Among these symptoms we focused on nasal obstruction and rhinorrhea as they are the most exhibited symptoms, as well as total serum IgE test. Unfortunately, re-estimation of specific IgE was not performed to avoid financial burden due to its high cost and in addition being a qualitative test.

After recording their symptoms, all patients included in the study were examined by anterior rhinoscopy and rigid endoscopic examination (Storz, Hopkins, 2.7 mm diameter, 0°, 30° Telescope) introduced as deeply as possible into the nostril for close examination of the nose. Nasal endoscopy facilitated evaluation of the degree of nasal turbinate hypertrophy as well as nasal discharge quantity. The videoendoscopic system consists of xenon light source (Karl Storz-Germany), contec-medical Endo-Camera and video recording apparatus.

In order to standardize the examination for all the patients, the participants were asked to arrive for examination in the morning without nose cleaning.

The nasal discharge and inferior turbinate hypertrophy were classified as follows:

Mild discharge: if the discharge (watery or mucoid) was in the middle meatus.

Moderate discharge: if the discharge was mainly in the middle meatus and floor of the nasal cavity.

Severe discharge: if the discharge was filling the nasal cavity including middle meatus, floor of nasal cavity and post nasal space.

On the other hand inferior turbinate hypertrophy was classified by anterior rhinoscopy into:

Mild: if turbinate hypertrophy does not obscure the view of middle turbinate.

Moderate: if turbinate hypertrophy obscures partially the middle turbinate.

Severe: if the turbinate hypertrophy obscures completely the middle turbinate.

Informed written consent was obtained from all patients' parents prior to their participation, and the study was designed as a single blind, randomized, parallel group trial, where the patients were randomly assigned to receive treatment in one of the following groups.

2.1. Group 1: LED phototherapy

In this group the 20 patients (12 males and 8 females), whose ages ranged from 7 to 17 years received intranasal illumination at 660 nm + mint tablets as a placebo in order to avoid the psychological refusal of the new modality of treatment introduced to the patients. The device used was Bionase unit from Youngdo Medical Instruments Co. Ltd. Korea. This instrument emits red light at 660 nm, it consists of a control box and two light emitting diode probe for intranasal use. A push-button switch on the control box activates the probe and the timer was adjusted at 4.5 min during which time 1.89 J of light energy is delivered from each unit. The probe was introduced into the patient's nostrils as deeply as possible and then the push button was pressed. Each nostril was subjected to energy stimulation (7 MW) 4 times per session, twice a week for 6 weeks.

2.2. Group 2: laser acupuncture

In this group the 20 patients (11 males and 9 females), whose ages ranged from 8 to 16 years, received low-level laser applied to acupoints + mint tablets as a placebo. The following acupoints (LI 19, LI 20, ST2, and ST4. ST6, ST7, ST17, ST36, SI18, BL2, GB14, GV24 and EXHN5) were selected and low-level laser was applied to it bilaterally, these acupoints were selected according to traditional Chinese medicine (TCM) theory.

Each acupoint was subjected to low-level laser (905 nm). The instrument used was spA version 2, 0, 2 Model Giotto (Italy) which emits laser at 905 nm of frequency 10,000 Hz and power 30 W. The laser probe was applied to the acupoints for 1.40 min during which 3 J of laser energy was delivered. The session lasted for 30 min twice weekly for total 12 sessions over 6 weeks.

Both patients and doctor used protective goggles.

2.3. Statistical methods

The data was coded and entered using the statistical package SPSS version 15. The data was summarized using descriptive

statistics: mean, standard deviation, minimal and maximum values for quantitative variables in clinical symptoms (rhinorrhea, and nasal obstruction) and in endoscopic findings (nasal discharge quantity and inferior turbinate size).

Statistical differences between groups were tested using ANOVA (analysis of variance) test for quantitative normally distributed variables while Nonparametric Mann–Whitney test and Kruskal–Wallis test were used for quantitative variables that are not normally distributed.

Testing the effect of intervention was done using Wilcoxon signed ranks test for quantitative variables. *P*-values less than or equal to 0.05 were considered statistically significant.

3. Results

There were no significant differences between the study groups with respect to age, sex ratio, duration of PAR symptoms or family history of PAR.

Due to difference in the reference range of serum IgE level according to age, IgE rise fold above normal level was used to determine its change.

The degrees of severity of symptoms prior to treatment of patients with allergic rhinitis in studied groups are summarized in

Table 1. Also nasal examination findings by both anterior rhinoscopy and endoscopy prior to treatment are summarized in Table 2.

Nasal obstruction caused by edematous congestion of inferior turbinate was the most common pre-treatment findings on nasal examination. Also nasal discharge was observed either watery or mucoid in the nasal cavity (Figs. 1 and 2).

Regarding group 1 (LED) a statistically significant difference was found between the severity symptom score before and 1 month after therapy indicating improvement of clinical symptoms (rhinorrhea, and nasal obstruction) ($P=0.001$). Despite the regression in the improvement score recorded after 3 months and 1 year there was still a significant difference in the severity score of symptoms before and after therapy regarding rhinorrhea and nasal obstruction (Table 1 and Fig. 3).

A statistically significant difference was also found between endoscopic findings before and 1 month after therapy regarding, nasal discharge quantity ($P=0.001$) and inferior turbinate size ($P=0.001$) (Table 2).

Serum IgE levels 1 month and 3 months after therapy were shown to be significantly reduced ($P=0.001$), while there was no significant difference between 1 month and 3 months post-treatment results ($P=0.065$) (Table 3).

Table 1
Clinical symptoms of the studied groups before and after treatment.

| Group | Symptoms | Severity | Before treatment | | After treatment | | | | | |
|-----------------------|-------------------|----------|------------------|---------|-----------------|---------|--------------|---------|----------|---------|
| | | | Number | Percent | One month | | Three months | | One year | |
| | | | | | Number | Percent | Number | Percent | Number | Percent |
| LED (1) | Rhinorrhea | Normal | 0 | 0% | 12 | 60% | 2 | 10% | 0 | 0% |
| | | Mild | 4 | 20% | 8 | 40% | 16 | 80% | 16 | 80% |
| | | Moderate | 4 | 20% | 0 | 0% | 2 | 10% | 4 | 20% |
| | | Severe | 12 | 60% | 0 | 0% | 0 | 0% | 0 | 0% |
| | Nasal obstruction | Normal | 0 | 0% | 14 | 70% | 10 | 50% | 10 | 50% |
| | | Mild | 6 | 30% | 6 | 30% | 10 | 50% | 10 | 50% |
| | | Moderate | 4 | 20% | 0 | 0% | 0 | 0% | 0 | 0% |
| | | Severe | 10 | 50% | 0 | 0% | 0 | 0% | 0 | 0% |
| Laser acupuncture (2) | Rhinorrhea | Normal | 0 | 0% | 12 | 60% | 12 | 60% | 0 | 0% |
| | | Mild | 8 | 40% | 8 | 40% | 8 | 40% | 10 | 50% |
| | | Moderate | 4 | 20% | 0 | 0% | 0 | 0% | 10 | 50% |
| | | Severe | 8 | 40% | 0 | 0% | 0 | 0% | 0 | 0% |
| | Nasal obstruction | Normal | 0 | 0% | 8 | 40% | 8 | 40% | 6 | 30% |
| | | Mild | 4 | 20% | 12 | 60% | 12 | 60% | 7 | 35% |
| | | Moderate | 4 | 20% | 0 | 0% | 0 | 0% | 7 | 35% |
| | | Severe | 12 | 60% | 0 | 0% | 0 | 0% | 0 | 0% |

Table 2
Nasal examination before and after treatment.

| Group | Nasal examination findings (by anterior rhinoscopy and endoscopy) | Severity | Before treatment | | After treatment by one month | |
|--------------------------------|---|----------|------------------|---------|------------------------------|---------|
| | | | Number | Percent | Number | Percent |
| | | | | | | |
| Mild | 2 | 10% | 14 | 40% | | |
| Moderate | 18 | 90% | 0 | 0% | | |
| Severe | 0 | 0% | 0 | 0% | | |
| Inferior turbinate hypertrophy | Normal | 4 | 20% | 12 | 60% | |
| | Mild | 8 | 40% | 8 | 40% | |
| | Moderate | 4 | 20% | 0 | 0% | |
| | Severe | 4 | 20% | 0 | 0% | |
| Laser acupuncture (2) | Discharge quantity | Normal | 0 | 0% | 8 | 40% |
| | | Mild | 12 | 60% | 12 | 60% |
| | | Moderate | 8 | 40% | 0 | 0% |
| | | Severe | 0 | 0% | 0 | 0% |
| | Inferior turbinate hypertrophy | Normal | 0 | 0% | 4 | 20% |
| | | Mild | 8 | 40% | 12 | 60% |
| | | Moderate | 12 | 60% | 4 | 20% |
| | | Severe | 0 | 0% | 0 | 0% |

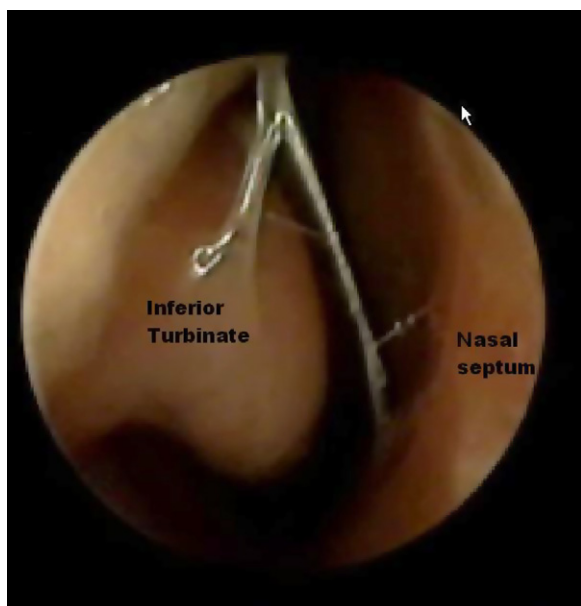


Fig. 1. Nasal mucosa and inferior turbinate of LED group before treatment.

In group 2, a statistically significant difference was found between the severity symptom score before and 1 month after therapy which persisted for 3 months follow-up ($P = 0.001$). Although this improvement regressed after 1 year there was still significant difference in severity score of symptoms before and 1 year after therapy (Table 1 and Fig. 4).

Statistically significant difference was found between endoscopic findings before and 1 month after therapy regarding to nasal discharge quantity ($P = 0.001$), and inferior turbinate size ($P = 0.001$) (Table 2).

Serum IgE levels were shown to be significantly reduced 1 month ($P = 0.003$) and 3 months ($P = 0.001$) after therapy, while there was no significant difference between 1 month and 3 months post-treatment results ($P = 0.60$) (Table 3).

All the results are listed in Tables 1–3 and Graphs 1–5.

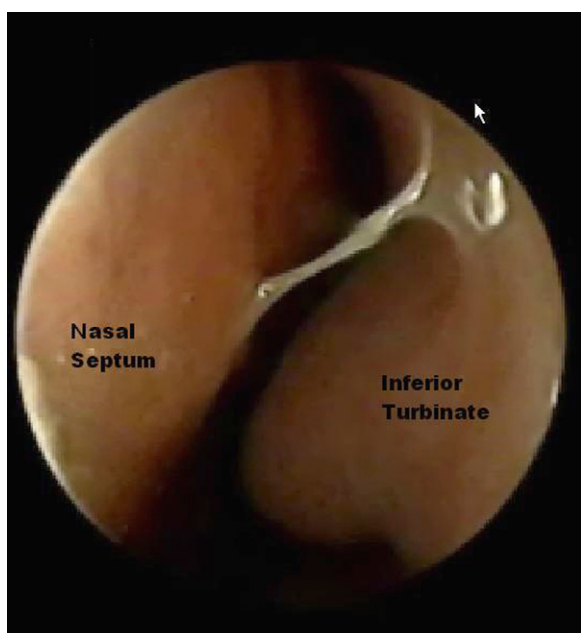


Fig. 2. Nasal mucosa and inferior turbinate of acupuncture group before treatment.

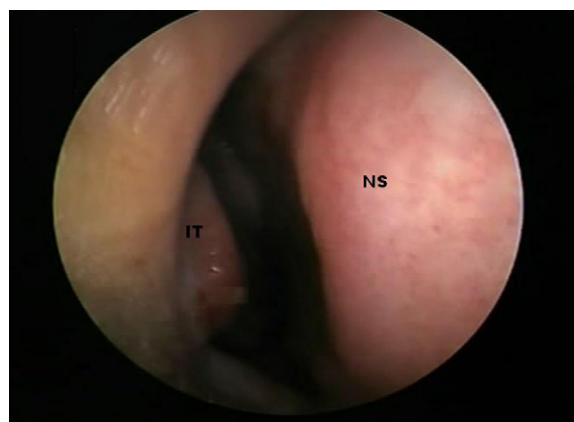


Fig. 3. Nasal mucosa and inferior turbinate of LED group 1 month after treatment.

Table 3
IgE before and after therapy among studied groups.

| Serum IgE change fold | LED | Acupuncture |
|-----------------------|-----------------|-----------------|
| Before therapy | | |
| Mean \pm SD | 2.63 \pm 2.50 | 1.10 \pm 0.50 |
| Median | 2.30 | 1.30 |
| Range | 0.20–9.50 | 0.20–1.60 |
| After 1 month | | |
| Mean \pm SD | 1.46 \pm 1.98 | 0.62 \pm 0.58 |
| Median | 1.00 | 0.50 |
| Range | 0.00–7.00 | 0.00–1.50 |
| After 3 months | | |
| Mean \pm SD | 1.24 \pm 0.74 | 0.48 \pm 0.44 |
| Median | 1.20 | 0.50 |
| Range | 0.10–2.70 | 0.00–1.20 |

SD: standard deviation.

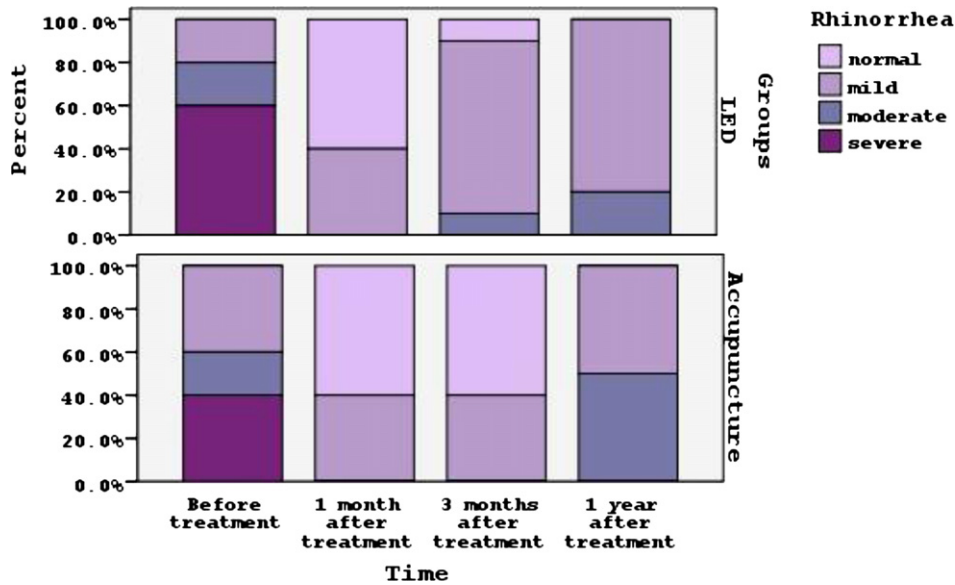
4. Discussion

Allergic rhinitis (AR) is defined as an abnormal inflammation of the membrane lining the nose which is mediated by immunoglobulin E (IGE). The clinical picture of AR includes sneezing, itchy nose, rhinorrhea and nasal congestion. Additionally, air way lining hypersensitivity, anomie, and inability to taste [1].

Current therapeutic options such as allergen avoidance, medication and immunotherapy are far from ideal. On the other hand, phototherapy has been proved to be an effective treatment modality in inflammatory and immune mediated diseases.

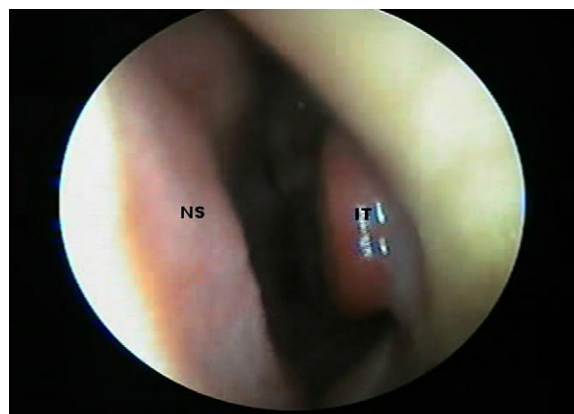

Fig. 4. Nasal mucosa and inferior turbinate of acupuncture group 1 month after treatment.



Graph 1. Presenting the variation in rhinorrhea between the two groups, before and after treatment.

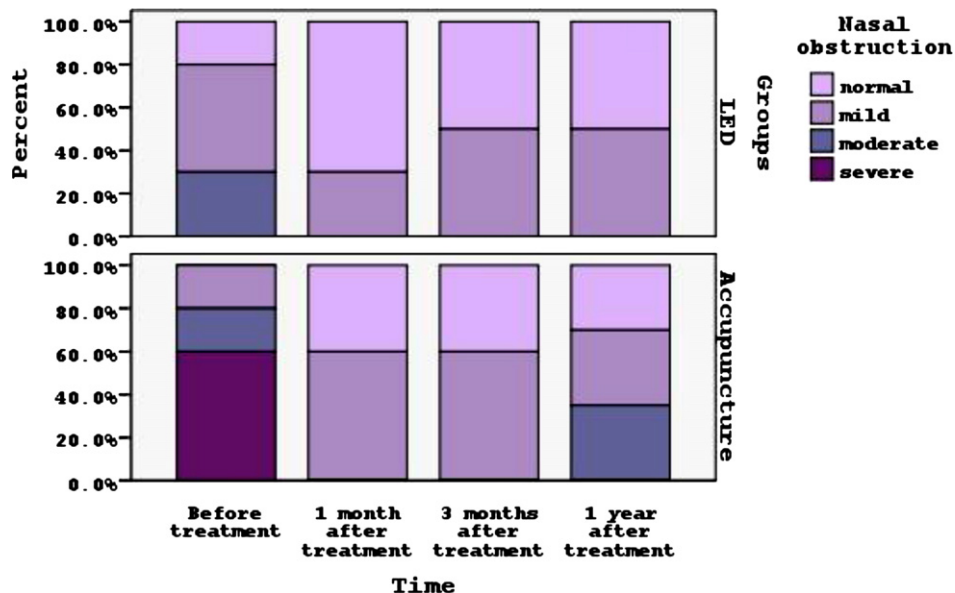
Development of new phototherapeutic devices made it possible to treat the inflammatory disease of the nasal mucosa. Also over the past decade the benefits of acupuncture have been reported in many clinical studies on allergic rhinitis.

The goal of our study is to assess and compare the beneficial effects of LED phototherapy and low-level laser acupuncture in treatment of allergic rhinitis.

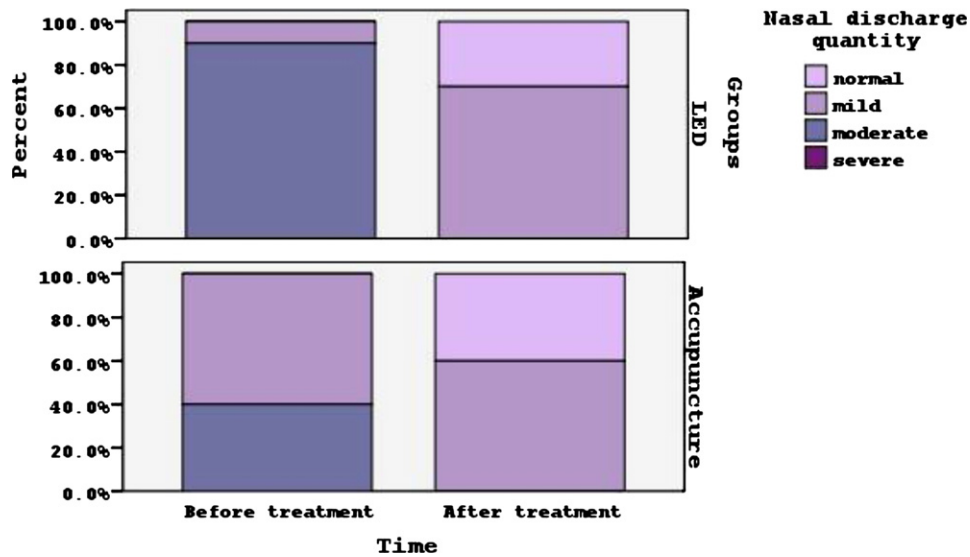
In a double-blind randomized study it was found that there was 70% improvement of clinical symptoms of allergic rhinitis after intranasal illumination by low-energy narrow-band phototherapy at 660 nm 3 times a day for 14 consecutive days. Also mild or marked objective improvement of edema of the middle turbinate was seen. The authors concluded that this type of phototherapy may be viewed as a useful additional approach in treatment of allergic rhinitis as it led to marked alleviation of symptoms. Patients were followed up for 1 year, and showed continuous improvement and persistent reduction of serum IgE, 3 months after therapy [28].

In 2009, Emberlin and Lewis found that phototherapy with infrared light (620 nm and 940 nm) can significantly reduce the severity of symptoms of allergic rhinitis with no known side effects which could offer a useful alternative or supplement to pharmacological treatment. However, the mechanism of action is not fully understood. Apart from light, some heat is generated; it may be that the effect of this heat could alter mucosal blood supply and inflammatory effects. It is clear that the near red light therapy was able to reduce symptoms during allergen challenge which are mainly sustained by massive release of histamine. This indicated that the therapy has modified this histamine release [29].

Our findings are in agreement with these findings as significant improvement was observed in symptoms severity score at 1 month post treatment. Patients in our study had daily symptoms despite of antihistamines and/or local steroid spray, which were stopped during LED therapy. The illumination selected was red light at 660 nm and the therapy continued for 6 weeks, 4 times per session, twice a week. The most severe symptoms of the pre-treated



Graph 2. Presenting the variation in nasal obstruction between the two groups, before and after treatment.



Graph 3. Presenting the variation in nasal discharge by nasal examination between the two groups, before and after treatment by 1 month.

patients were rhinorrhea and nasal obstruction. The improved clinical symptoms started from the second to third week of treatment and the improvement was continuous thereafter throughout the follow up period up to 1 year. Also we found that the serum IgE level was reduced after the 6 weeks period of treatment and this reduction lasted up to 3 months follow up period. The patients tolerated the treatment well, and no adverse effects were observed during the period of treatment and follow up.

Both illuminations at visible (400–800 nm) and infrared (800–1000 m) range were shown to be of therapeutic benefit, but these two types of illumination differ markedly in their photochemical and photophysical properties. The visible light probably stimulates the cascade of metabolic events at the level of respiratory chain of mitochondria, including the formation of reactive oxygen species, through a photochemical reaction, whereas infrared illumination does so by activating enzymes and probably also Ca⁺ channels in the membranes [30].

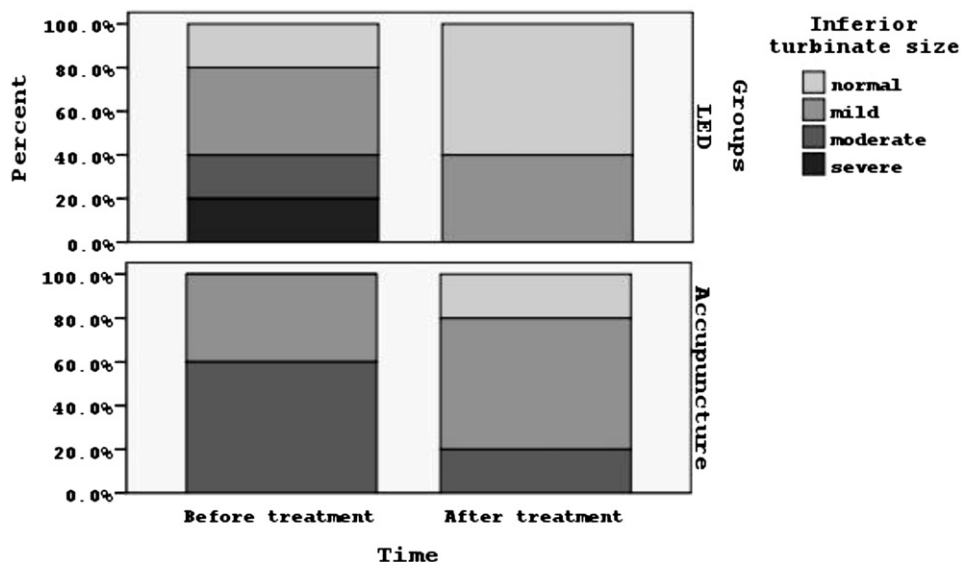
Although different mechanisms are involved when light sources with different ranges of wavelengths are employed,

phototherapy represents a non-invasive, low cost and minimal side effects alternative intervention in treatment of allergic rhinitis.

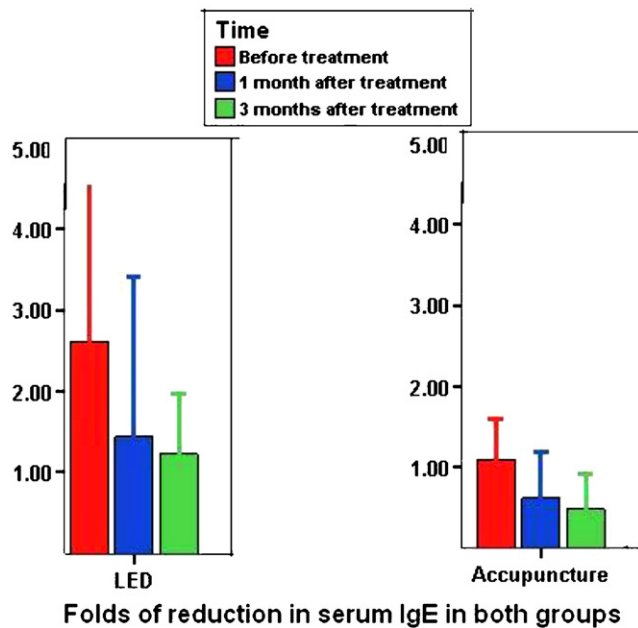
Over the last decade, many literature reports proved that acupuncture is a useful complementary or alternative treatment option for allergic rhinitis in both adult and children. Many randomized controlled trials for allergic rhinitis allowed the concomitant use of acupuncture and pharmacological medication for symptomatic relief of AR. Hence the interpretation of the efficacy of acupuncture alone was reported limited [23,25,26,31–34].

As for treatment sessions, high quality randomized, sham controlled trials used a total of 16 acupuncture sessions, twice a week for 8 weeks and followed up for another 12 weeks. After the treatment period there was significantly greater reduction from base line in total nasal symptom scores which persisted for another 12 weeks in real acupuncture group than in the sham treatment group [33,34].

In contrast to the aforementioned studies, the patients in our study stopped any conventional medication two weeks prior to



Graph 4. Presenting the variation in inferior turbinate size by nasal examination between the two groups, before and after treatment by 1 month.



Graph 5. Presenting the folds of reduction in serum IgE throughout the follow up period in the two groups, before and after treatment.

enrollment in the study and were not allowed to use any AR symptoms relievers throughout the course of treatment and follow-up period. Hereby, we report a statistically significant improvement in symptom severity scores after treatment which lasted for 1 year compared to pre-treatment scores.

Our results are in agreement with those of Kim et al. in their randomized controlled trial to evaluate the effectiveness of needle acupuncture in patients with PAR compared to sham acupuncture. PAR symptom relievers were not allowed, and they added one additional session of acupuncture treatment per week, i.e. 12 sessions over 4 weeks. This addition was assumed to compensate for the reduced effect of not using conventional medication, and they provided evidence for its effectiveness as a sole treatment for PAR [24].

Regarding treatment duration, we consider that 12 sessions over 6 weeks to be sufficient period of time to obtain clinically relevant improvement which was noticed 2–3 weeks after the start of treatment. The most severe symptoms of the pre-treated patients were nasal obstruction and rhinorrhea. By time the participants showed continuous improvement in all PAR symptoms throughout the short term follow up (3 months), but there was slight recurrence of rhinorrhea, and nasal obstruction at the end of the follow up period (1 year).

Endoscopic examination of our patients 1 month post treatment revealed significant reduction in the size of the inferior turbinate, which is in agreement with the results of Hu and Yan [35].

Although several studies have demonstrated positive outcomes of acupuncture in various allergic conditions, the mechanism of action of acupuncture are yet to be elucidated. Acupuncture has been reported to inhibit the synthesis of cytokines, such as interleukin-6 and interleukin-10 in patients with allergic rhinitis [36,37]. Acupuncture also affect cellular immunity by regulating CD3 and CD4 T cells, as well as stimulating the release of neuropeptides involved in neurogenic inflammation, such as beta-endorphin [38]. Other studies showed that acupuncture increases the nitric oxide level in treated region, resulting in increased local blood circulation [39].

Consistent with reported acupuncture studies for allergic rhinitis and specific acupuncture safety study [40], we found that

laser acupuncture was well tolerated and no adverse events were serious enough to result in participant withdrawal from the trial. So we conclude that low-level laser acupuncture may provide a safe and effective option for the symptomatic treatment of PAR.

To the best of our knowledge, no other randomized controlled trials comparing the effect of intranasal phototherapy by LED light or low-level laser acupuncture in children suffering from PAR has been reported. However in our present study we reported significant improvement detected in the symptoms severity scores and reduced serum IgE level after therapy and throughout the follow up period as well as reduction of inferior turbinate size and quantity of nasal discharge.

Difference between the outcomes of LED phototherapy and low-level laser acupuncture groups was not marked, but LED phototherapy had profound and long lasting improvement effects on rhinitis symptoms than low-level laser acupuncture which can be attributed to the fact that it was introduced intranasal and its effect was directly on the nasal mucosa in comparison with the laser acupuncture which was performed on peripheral acupoints according to Chinese medicine.

Our data confirmed that both phototherapy and low-level laser acupuncture are an effective, safe and a non-invasive treatment modality for allergic rhinitis, although further more detailed follow up and comparisons with conventional therapy are needed.

We recommend using phototherapy modality in the form of LED or low level laser acupuncture as an alternative option in some cases or a complimentary treatment in others.

References

- [1] P. David, M.D. Skoner, Allergic rhinitis: definition, epidemiology, detection and diagnosis, *J. Allergy Clin. Immunol.* 108 (2001) 2–8.
- [2] P.A. Pittsburgh, Advances in allergic disease: an update for the new millennium, *J. Allergy Clin. Immunol.* 105 (2000) S616–S621.
- [3] M. Rosenwasser, Intranasal corticosteroids in treatment of pediatric allergic rhinitis, *Am. J. Med.* 113 (9A) (2002) 175–245.
- [4] M.S. Dykewicz, S. Fineman, D.P. Skoner, R. Nicklas, R. Lee, J. Moore, et al., Diagnosis and management of rhinitis complete guideline of the joint task force on practice parameters in allergy, asthma and immunology, *Ann. Allergy Asthma Immunol.* 81 (1998) 478–518.
- [5] J. Plevkova, M. Brozmanova, R. Pecova, M. Tatar, Effects of intranasal histamine on the cough reflex in subjects with allergic rhinitis, *J. Physiol. Pharmacol.* 56 (Suppl. 4) (2005) 185–195.
- [6] J. Day, Pros and cons of the use of antihistamines in managing allergic rhinitis, *J. Allergy Clin. Immunol.* 105 (6 pt 2) (1999) 610–615.
- [7] F. Philip, Advances in allergic disease: as update for the new millennium, *J. Allergy Clin. Immunol.* 102 (2000) 8516–8528.
- [8] A. Sheikh, B. Hurwitz, House dust mite avoidance measures for perennial allergic rhinitis: a systemic review of efficacy, *Br. J. Gen. Pract.* 53 (2003) 518–522.
- [9] G.K. Scadding, Corticosteroids in the treatment of pediatric allergic rhinitis, *J. Allergy Clin. Immunol.* 108 (2001) 559–564.
- [10] J. Bousquet, P. Van Cauwenberge, N. Khaltaev, World Health Organization: allergic rhinitis and its impact on asthma, *J. Allergy Clin. Immunol.* 108 (2001) 147–156.
- [11] P.A. Pittsburgh, Therapeutic approaches to allergic rhinitis: treating the child, *J. Allergy Clin. Immunol.* 105 (2000) S638–S646.
- [12] P.A.M. Camargos, C.C. Ibiapina, L. Lasmar, A. Cruz, Obtaining concomitant control of allergic rhinitis and asthma with a nasally inhaled corticosteroid, *Allergy* 62 (2007) 310–316.
- [13] T.W. Guilbert, W.J. Morgan, R.S. Zeiger, D.T. Mauger, S.J. Boehmer, S.J. Szeffler, et al., Long-term inhaled corticosteroids in preschool children at high risk for asthma, *N. Engl. J. Med.* 354 (2006) 1985–1997.
- [14] E. November, E. Galli, F. Landi, C. Cafarelli, M. Pefferi, E. De Marco, et al., Coseasonal sublingual immunotherapy reduces the development of asthma in children with allergic rhinoconjunctivitis, *J. Allergy Clin. Immunol.* 114 (2004) 851–857.
- [15] Dianne E. Campbell, Sublingual immunotherapy for children: are we there yet? Defining its role in clinical practice, *Paediatr. Respir. Rev.* 10 (2009) 69–74.
- [16] A.L. Koreck, Z. Csoma, L. Bodai, F. Ignacz, A.S. Kenderessy, E. Kadocsa, et al., Rhinophototherapy: a new therapeutic tool for the management of allergic rhinitis, *J. Allergy Clin. Immunol.* 115 (2005) 541–547.
- [17] A. Koreck, A. Szechenyi, M. Morocz, A. Cimpean, Z. Bella, E. Garaczi, et al., Effects of intranasal phototherapy on nasal mucosa in patients with allergic rhinitis, *J. Photochem. Photobiol. B* 89 (2007) 163–169.
- [18] Z. Csoma, A. Koreck, F. Ignacz, Z. Bor, G. Szabo, L. Bodai, et al., PUVA treatment of the nasal cavity improves the clinical symptoms of allergic rhinitis and inhibits the immediate-type hypersensitivity reaction in the skin, *J. Photochem. Photobiol. B* 83 (2006) 21–26.

- [19] C. Cingi, A. Yaz, H. Cakli, E. Oz Udogru, C. Kecik, C. Bal, The effect of phototherapy on quality of life in allergic rhinitis cases, *Eur. Arch. Otorhinolaryngol.* 266 (2009) 1903–1908.
- [20] L. Hod, J. Tuner, Low-level laser therapy (LLLT) versus light-emitting diode therapy (LEDT): What is the difference? in: *Proc. SPIE 4166, Laser Florence 99: A Window on the Laser Medicine World*, 90, 2000, <http://dx.doi.org/10.1117/12.38946>.
- [21] T. Karu, Molecular mechanism of therapeutic effect of low intensity laser radiation, *Laser Life Sci.* 2 (1988) 53–74.
- [22] T. Karu, *The Science of Low Power Laser Therapy*, Gordon and Beach Science Publishers, Amsterdam, the Netherlands, 1998.
- [23] B. Brinkhaus, J. Hummelsberger, R. Kohnen, J. Seufert, C.H. Hempen, H. Leonhardy, et al., Acupuncture and Chinese herbal medicine in the treatment of patients with seasonal allergic rhinitis: a randomized-controlled clinical trial, *Allergy* 59 (2004) 953–960.
- [24] J.I. Kim, M.S. Lee, S. Jung, S. Choi, Acupuncture for persistent allergic rhinitis: a multi-centre, randomized, controlled trial protocol, *Trials* 10 (2009) 54.
- [25] G. Stux, B. Berman, B. Pomeranz, *Basic of Acupuncture*, 5th ed., Springer, London, UK, 2003.
- [26] V. Hopwood, M. Lovesey, S. Mokone, *Acupuncture & Related Techniques in Physical Therapy*, Elsevier Science Ltd., London, UK, 2003.
- [27] T. Karu, Depression of the genome after irradiation of human lymphocytes with He-Ne Laser, *Laser Ther.* 4 (1992) 5–24.
- [28] I. Neuman, Y. Finkelstein, Narrow-band red light phototherapy in perennial allergic rhinitis and nasal polyposis, *Ann. Allergy Asthma Immunol.* 78 (1997) 399–405.
- [29] J.C. Emberlin, R.A. Lewis, Pollen challenge study of a phototherapy device for reducing the symptoms of hay fever, *Curr. Med. Res. Opin.* 25 (7) (2009) 1635–1644.
- [30] F.E.R. Simons, J.D. Reggin, J.R. Roberts, K.J. Simons, Benefit/risk ratio of the antihistamines (H1-receptor antagonists) terfenadine and chlorpheniramine in children, *J. Pediatr.* 124 (1994) 979–983.
- [31] B. Brinkhaus, C.M. Witt, S. Jena, B. Liecker, K. Wegscheider, S.N. Willich, et al., Acupuncture in patients with allergic rhinitis: a pragmatic randomized trial, *Ann. Allergy Asthma Immunol.* 101 (2008) 535–543.
- [32] C.C. Xue, R. English, J.J. Zhang, Teal effect of acupuncture in the treatment of seasonal allergic rhinitis: a randomized controlled clinical trial, *Am. J. Chin. Med.* 30 (2002) 1–11.
- [33] D.K. Ng, P.Y. Chow, S.P. Ming, S.H. Hong, S. Lau, D. Tse, et al., A doubled-blind randomized, placebo-controlled trial of acupuncture for the treatment of childhood persistent allergic rhinitis, *Pediatrics* 114 (2004) 1242–1247.
- [34] C.L. Xue, A. Xuedong, T.p. Cheung, C.D. Costa, G.B. Lenon, F.C. Thien, et al., Acupuncture for persistent allergic rhinitis: a randomized, sham-controlled trial, *Med. J. Aust.* 187 (2007) 337–341.
- [35] K.H. Hu, D.N. Yan, Clinical effects of phototherapy to Shangyingxiang Xue on 31 patients with allergic rhinitis, *J. Changchun Univ. Tradit. Chin. Med.* 25 (4) (2009) 266–267.
- [36] F.B. Petti, A. Liguori, F. Ippoliti, Study on cytokines IL-2 IL-6, and IL-10 in patients of chronic allergic rhinitis treated with acupuncture, *J. Tradit. Chin. Med.* 22 (2) (2002) 104–111.
- [37] H.S. Shiue, Y.S. Lee, C.N. Tsai, Y.M. Hsueh, J.R. Sheu, H.H. Chang, et al., DNA microarray analysis of the effect on inflammation in patients treated with acupuncture for allergic rhinitis, *J. Altern. Complement Med.* 14 (2008) 689–698.
- [38] J.S. Han, Acupuncture and endorphins, *Neurosci. Lett.* 361 (1–3) (2004) 258–261.
- [39] M. Tsuchiya, E.F. Sato, M. Inoue, A. Asada, Acupuncture enhances generation of nitric oxide and increase local circulation, *Anesth. Anal.* 104 (2) (2007) 301–307.
- [40] H. Macpherson, K. Thomas, S. Walters, M. Fitter, The York acupuncture safety study: prospective survey of 34,000 treatments by traditional acupuncturists, *BMJ* 223 (2001) 486–4871.